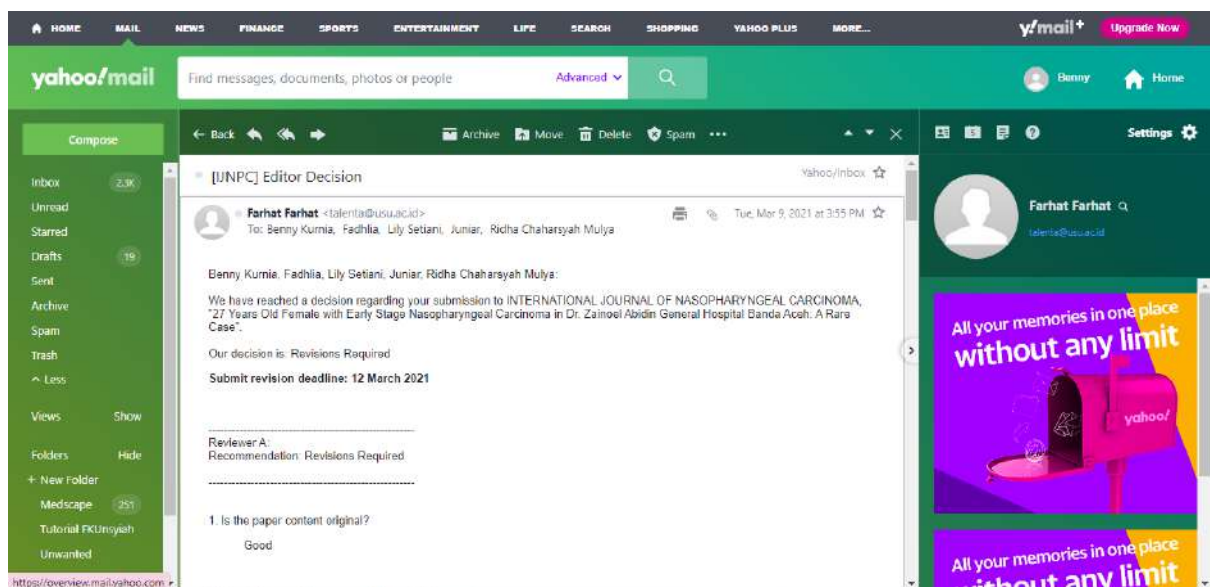
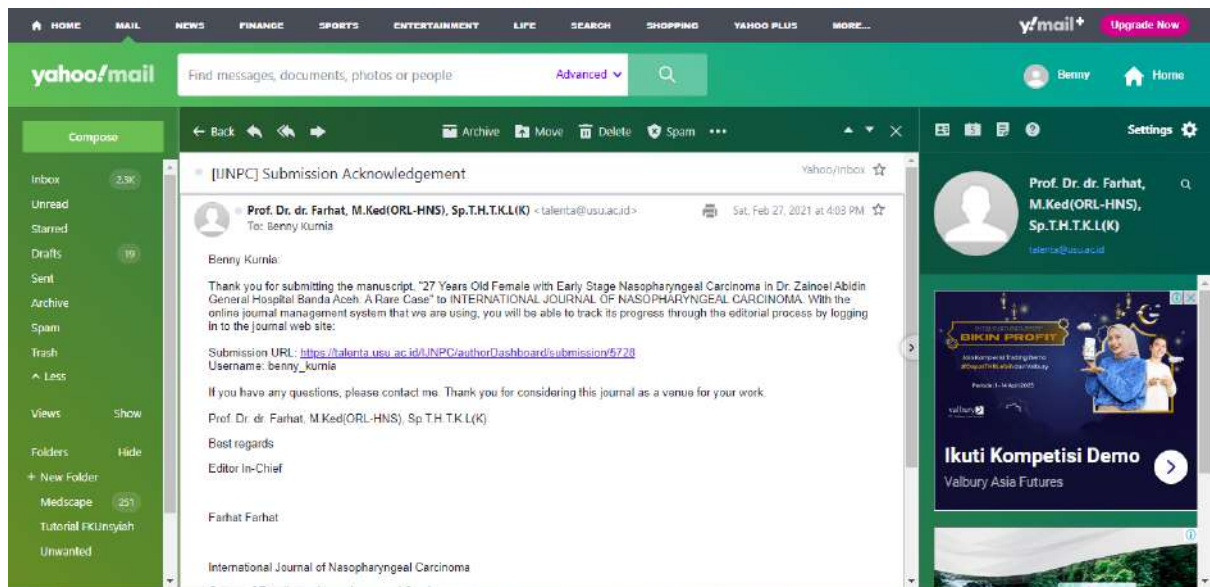
CASE REPORT

27 Years Old Female with Early Stage Nasopharyngeal Carcinoma in Dr. Zainoel Abidin General Hospital Banda Aceh: A Rare Case

Abstract

Introduction: Epistaxis and headache are common symptoms of outpatient at ENT office, sometime overlooked by clinician and patient as well as the symptom of early stage of nasopharyngeal cancer. Taking a detail history and physical examination of head and neck will lead clinician to have a proper diagnosis of nasopharyngeal cancer

Case Report: We reported a case of 27 year old woman patient with chief complaints recurrent nosebleeds since 2 months ago frequently one to two times a week. Patients also complained of mild headaches, but getting better by taking a rest and patient also had a history of tinnitus since 2 month ago. The patient has a habit of consuming salted fish and preservative food since childhood. Based on his history of illness, physical examination, imaging, and histopathology, we concluded that he was diagnosed with Nasopharyngeal Carcinoma T1N0M0, and the patient are going to referred to North Sumatera or central java to get radiotherapy.

Conclusion: Early stage of nasopharyngeal cancer is a rare condition at Aceh, the fastest we found early stages will increased survival rate.

Keywords: Early symptom of nasopharyngeal carcinoma, Epistaxis, Headache

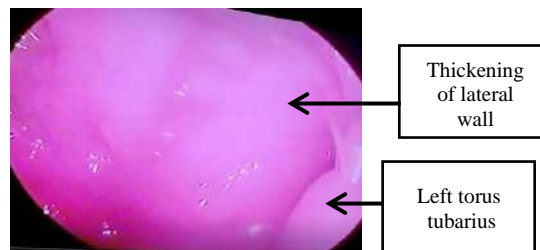
CASE REPORT

A 27 year old woman came to the Ear Nose Throat Head and Neck polyclinic-Dr. Zainal Abidin General Hospital Banda Aceh in January 2021. The patient complained of recurrent nosebleeds that had been experienced since the previous 2 months, nosebleeds is recurrent with a frequency of one to two times per week. The blood that comes out is not much, sometimes there are only blood spots when the patient blows his nose. In addition, patient also complained of mild headaches and getting better by taking a rest, but headaches often recur. Headache is felt especially on the forehead. Apart from that the patient also had a history of tinnitus. History of double eye vision and of lumps around the neck was denied.

The patient has a habit of consuming salted fish quite often, besides that the patient also likes to consume preservative foods such as instant noodles since childhood. There is no family member who has a history of cancer.

Anterior rhinoscopy examination found a minimal clot in the left nasal cavity, and no other abnormalities were seen.

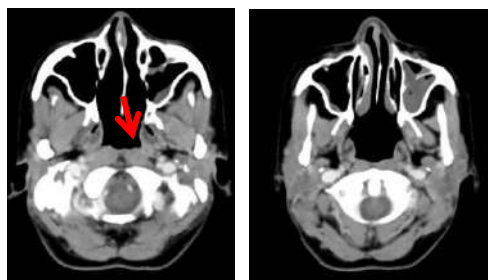
On 04th February 2021 the patient underwent a rigid nasopharyngoscopy examination at polyclinic to evaluate the cause of recurring nosebleeds. Before that, the patient underwent a screening of COVID-19 and the result of RT-PCR SARS-cov-2 was negative.



Picture 1. Rigid nasopharyngoscopy on February 04th 2021

The result of Rigid nasopharyngoscopy found there was a thickening at lateral left nasopharyngeal surface, especially around the fossa rosenmuler. We did informed consent to performed a nasopharyngeal biopsy to determine the histopathology of thickening area. The biopsy was performed in Ear Nose Throat Head and Neck polyclinic under local anesthesia using biopsy forceps and 0 degrees rigid telescope and obtained 1 mm of tissue from the lateral left nasopharyngeal wall. Then the sample was sent to Pathology Anatomy Laboratory at Dr. Zainoel Abidin Hospital, after a week we got the histopathological result was non keratinizing squamous cell carcinoma.

On the 15th February 2021, we performed an HRCT of the nasopharynx with contrast and we have a result two day after.



Picture 2. CT scan of the nasopharynx using contrast showed thickening of the nasopharyngeal wall

The nasopharyngeal wall was thickened on a CT scan and there is no other visible mass and hypervascularisation. Based on history, physical examinations and all diagnostic procedure such as CT scan nasopharynx with contrast, Rigid nasopharyngoscopy plus biopsy, chest X-rays and histopathologic result, we diagnosed a patient with nasopharyngeal carcinoma T1N0M0. We informed her to refer to North Sumatra or Central Java to have radiotherapy. We still do not have a central radiotherapy yet at our hospital.

DISCUSSION

At the pharyngeal recess or Fossa of Rosenmüller, the highest incidence of NPC inside the nasopharynx is found (82 percent), 12 percent occur in the midline and 6-10 percent of patients displayed normal endoscopic presence of nasopharyngeal mucosa. Fossa of Rosenmüller, which is superior and posterior to the Eustachian tube elevation. This Rosenmüller fossa, which is coated with mixed stratified epithelium and ciliated epithelium with regions of a discontinuous attenuated reticular epithelium, is the lateral extension of the nasopharynx. So-called reticular epithelium in the nasopharyngeal regions, NPC can emerge from a special transitional epithelium and, It is likely that the origin of the cells could be [1]. In this case the tumour did not appear exophytic but highly suspicious as asymmetric surface of both lateral surface of nasopharyngeal wall.

Generally in Indonesia especially Aceh it is very rare we found early stages of NPC. Dr. Zainoel Abidin General Hospital Banda Aceh as a top referral hospital in Aceh always received advanced diseases of NPC from all districts at Aceh. As we reported before in 2016-2017, The characteristic of NPC at Dr. Zainoel Abidin General Hospital Banda Aceh the most frequent was age ranged 41-60 years (44%), and incidence is higher in males than females and all of the subjects were locally advanced and advanced diseases. No one of them came in early stages [2]. Other study reported about nasopharyngeal carcinoma in childhood, the age ranged 12-16 years were 47%, and with the average age was 17.2 years [3]. The latest study reported in 2019, The youngest patient is 13 year old and the oldest is 79 year old. Most common average age are between 36-65 year old and none of all as an early stages [4].

Sign and Symptoms of nasopharyngeal carcinomas frequently present with one or more of 4 groups of symptoms. They consist of otologic symptoms such as deafness and tinnitus, a small tumor in the fossa of Rosenmüller of the nasopharynx may cause Eustachian tube Nasal signs such as nasal obstruction, epistaxis, and discharge (these symptoms are related to the presence of tumor mass in the nasopharynx). Cranial nerve paralysis, normally 5th and 6th cranial nerves, which is

connected to the superior tumor extension contributing to skull base erosion, the patient may experience headache, diplopia, facial pain, and masses of numbness and neck.. Nasal signs such as nasal obstruction, epistaxis, and discharge (these symptoms are related to the presence of tumor mass in the nasopharynx). Cranial nerve paralysis, normally 5th and 6th cranial nerves, which is connected to the superior tumor extension contributing to skull base erosion, the patient may experience headache, diplopia, facial pain, and masses of numbness and neck. [5, 6]. This case presented recurrent nosebleed and mild headache.

Nasal obstruction, epistaxis, and discharge are all signs of nasal obstruction (these symptoms are related to the presence of tumor mass in the nasopharynx). The patient may experience headache, diplopia, facial pain, and masses of numbness and neck with cranial nerve paralysis, usually 5th and 6th cranial nerves, which is related to the superior tumor extension leading to skull base erosion. endoscope, however, is inferior to that of the rigid endoscope [7, 8].

Computed tomography (CT) has long been utilized for staging nasopharyngeal carcinoma especially to detect skull base tumor involvement with lytic or sclerotic lesions. However, now, in some centers, MRI has replaced the use of CT for primary and nodal staging. MRI is considered to be an accurate examination to diagnose nasopharyngeal carcinoma. Subclinical nasopharyngeal carcinomas that are missed at endoscopy can be detected by MRI. Nasopharyngeal carcinomas in MRI usually present with intermediate signal intensity on T2 weighted images and low signal intensity on T1 weighted images. When suspicion of early-stage nasopharyngeal carcinoma arises, MRI can be an option if endoscopic examination does not reveal the expected signs. CT is still needed in radiotherapy planning [9, 10].

We have sufficient facilities to worked up of NPC patient, but not the modality of treatment. Histopathology result is still as a gold standart for diagnosis of NPC. In Addition It remains unclear the precise contribution of EBV infection to NPC growth. In NPC tumor cells, the presence of monoclonal EBV episomes suggests that virus infection precedes the clonal expansion of the population of malignant cells. However, the absence of epithelial EBV infection from individuals at high risk of developing nasopharyngeal carcinoma in normal nasopharyngeal biopsies indicates that epithelial infection may not be the initiating event of virus-associated carcinogenesis. IEBV infection as defined by in situ hybridization to the EBER RNAs is present in high-grade (severe dysplastic and carcinoma in situ) preinvasive lesions in the nasopharynx but not in low-grade disease or histologically normal nasopharyngeal epithelium. Both high-grade and carcinoma in situ lesions bear monoclonal EBV genomes.n high-grade (severe dysplastic and carcinoma in situ) preinvasive lesions in the nasopharynx but not in low-grade disease or histologically normal nasopharyngeal epithelium,

EBV infection as identified by in situ hybridization to the EBER RNAs is found. Monoclonal EBV genomes are borne by both high-grade and carcinoma in situ lesions. [11, 12].

There are three pathological subtypes of nasopharyngeal carcinoma: keratinizing squamous, non-keratinizing, and basaloid squamous, according to the World Health Organization. According to the World Health Organization, there are three pathological subtypes of nasopharyngeal carcinoma: keratinizing squamous, non-keratinizing, and basaloid squamous. Non-keratinizing nasopharyngeal carcinoma can be divided into differentiated and undifferentiated tumours. The non-keratinizing subtype constitutes most cases in endemic areas (>95%) and is predominantly associated with Epstein-Barr virus (EBV) infection. EBV can be detected in the tumor cells of almost all nonkeratinizing carcinoma but rarely in keratinizing nasopharyngeal carcinoma [11-13]. In addition, Almost 100 percent of WHO type III is associated with Epstein Barr Virus (EBV) infection, in particular. High IgG and IgA antibody responses to viral capsid antigen (VCA), early antigen (EA), and Epstein Barr Nuclear antigen (EBNA) suggest this (EBNA). 2-10 years before the appearance of the tumor, increased IgA NPC character antibodies can be identified. This occurs as a result of reactivation of EBV infection [14-16]. In our hospital we were not routinely doing the test for EBV.

We routinely performed HRCT of nasopharynx with contrast to determine the stage of NPC at least for Tumour level (T) and locoregional metastasis (N) as well as laboratory test and ultrasonography and chest x-ray to looking for distant metastasis (M). We used TNM system from AJCC 8th edition 2017. The 2021 National Comprehensive Cancer Network (NCCN) guideline is used for the most recent staging system and management of head and neck malignancies [17].

Treatment and prognosis of nasopharyngeal cancer depend on the type of tissue, histological characteristics, and TNM staging. Patients with T1N0M0 nasopharyngeal carcinoma should be treated with definitive radiotherapy alone, including elective Radio therapy to the neck. Radiotherapy alone is the standard treatment for early stage nasopharyngeal carcinoma and five-year overall survival rate of 84 to 90% can be achieved even with the use of conventional treatment technique. In general, patients with stage I and II nasopharyngeal carcinoma are treated by radiation only, whereas stage III and stage IV patients are treated by concurrent chemotherapy and radiation. In addition, evidence suggests that patients diagnosed with stage IV nasopharyngeal carcinoma with locally advanced disease may be better controlled by neoadjuvant cisplatin followed by chemoradiation. In this case, the patient was planned refer to hospital that can performed radiation therapy. For T1N0 patients, radiotherapy alone is given with a radical dose of 66-70 Gy daily Monday-Friday in 6-7 weeks [13].

Early-stage T1 and T2 nasopharyngeal cancers have very high (> 95%) 5-year locoregional control rates. The 5-year overall survival rates are significantly lower, 70–75%, emphasizing the propensity of these lesions to metastasize [17].

Since we do not have central radiotherapy, all the patient who had diagnosed as NPC with advanced stages, they underwent induction chemotherapy at Dr. Zainoel Abidin General Hospital Banda Aceh and if possible for them to continued radiotherapy in out of city.

A thorough examination and awareness of nasopharyngeal carcinomas early signs and symptoms will made it possible for clinicians to detect an early-stage nasopharyngeal carcinoma. Stage, WHO type and age at diagnosis are important prognostic factors for survival for nasopharyngeal carcinoma patients. With early diagnosing, we can deliver immediate therapy and will increase survival rate. Usually patient come to ENT specialist on advanced stage where complaints from patient are increasing and management to treat patient more complex [17].

However the early diagnosing of nasopharyngeal carcinoma can be difficult to determine because the post nasal space is relatively inaccessible examination, because of that the anamnesis must be clear. Early cancers of the nasopharynx produce minimal and trivial symptoms that may be neglected by the patients and undetected by physicians. Moreover, sometimes patients consult doctors of different specialties who have lack experience in managing nasopharyngeal carcinoma [14, 15]. Usually patient come to ENT specialist at advanced stage when neck node had appeared.

CONCLUSION

This case bring us new hope that awareness of early symptom of NPC have arised at community based. The patient came from west Aceh where geographically about 300 kilometres far away from Banda Aceh. The Insurance from government also give contribution to get more easier to medical access.

REFERENCE

- [1] Anne WML, Maria LL, Wai TN. Nasopharyngeal Carcinoma; From etiology to clinical practise. United Kingdom: Elsavier publisher; 2019. Page 46-47.

- [2] Kurnia B, Kamarlis RK, Kamal FK. Characteristic of Nasopharyngeal Carcinoma in Aceh 2016-2017. *International journal of nasopharyngeal carcinoma*. 2019, Vol. 01, No. 01, 2019 | 24-29. DOI: 10.32734/ijnpc.v1i1.958
- [3] Setiani L, Fadhliia, Kurnia B, Karnita Y. Characteristics of Nasopharyngeal Carcinoma in Children and Adolescents in dr. zainoel abidin general hospital banda aceh. *International journal of nasopharyngeal carcinoma*. 2019, Vol. 01, No. 03, 2019; 93-96. DOI: 10.32734/ijnpc.v1i03.2062.
- [4] Fadhliia, Ferawati, Irnawati. Management of Nasopharyngeal Cancer in DR. Zainoel Abidin General Hospital Banda Aceh. *International journal of nasopharyngeal carcinoma*. 2019, Volume 1, No 1, 2019 | 50-54. DOI: 10.32734/ijnpc.v1i2.1 | 34
- [5] Yvonne C, John CG. K.J.LEE'S Essential Otolaryngology Head and Neck Surgery. Eleventh Edition. New York: McGraw-Hill Education; 2016. Page 722.
- [6] Tobing IN. Early-stage Nasopharyngeal Carcinoma: A Case Report. *International journal of nasopharyngeal carcinoma*. 2019, Vol. 01, No. 02, 2019 | 75-77. DOI: 10.32734/ijnpc.v1i2.1133.
- [7] Ashley W, James BS. Ballenger's Otolaryngology Head and Neck Surgery 18. United Kingdom: People's Medical Publishing House; 2016. Page 4389, 4397.
- [8] Network NCC. NCCN Clinical Practice Guidelines in Oncology (NCCN® guidelines): head and neck cancers. Version 1.2021.
- [9] Tobing IN. Early-stage Nasopharyngeal Carcinoma: A Case Report. *International journal of nasopharyngeal carcinoma*. 2019, Vol. 01, No. 02, 2019 | 75-77. DOI: 10.32734/ijnpc.v1i2.1133.
- [10] Tsang CM, Lo KW, Nicholls JM, Huang SCM, Tsao SW. Pathogenesis of Nasopharyngeal Carcinoma: Histogenesis, EpsteinBarr Virus Infection, and Tumor Microenvironment. Elsevier Inc: China; 2018. Page 60.
- [11] Chen YP, Chan AT, Blanchard P, Sun Y, Jun-ma. Nasopharyngeal Carcinoma. *The lancet Journal*. 2019, Volume 394. [http://dx.doi.org/10.1016/S0140-6736\(19\)30956-0](http://dx.doi.org/10.1016/S0140-6736(19)30956-0).
- [12] Shah J, Patel S, Singh B, Wong R. Jatin Shah's Head and Neck Surgery and Oncology. Fifth Edition. Elsevier: Sidney; 2020. Page 299.
- [13] Flint PW, Haughey BH, Lund VJ, Niparko JK, Robbins KJ, Thomas JR, Lesperance MM. Cummings Otolaryngology Head and Neck Surgery. Sixth Edition Volume 1. Saunders Elsevier: Philadelphia; 2015. Page 1423.
- [14] John CW, Raymond WC. Scott-Brown's Otolaryngology Head and Neck Surgery Volume three. Eighth Edition. France: CRC Press; 2019. Page 93.

- [15] Adham M, Zhafira AS, Paramitha AC, Adhyatmoko B, Hanafi G, Hiksas R, Culham K. The Importance of Early Detection of Nasopharyngeal Carcinoma: A Case Report in Scientific Paper Compilation 1st National Conference of Nasopharyngeal Carcinoma, Prevention is better than cure. USU Press: Medan; 2018. Page 136.
- [16] Lalwani AK. Current Diagnosis and Treatment Otolaryngology Head and Neck Surgery. Second edition. Mc Graw Hill Lange: United State of America; 2008. Page 1423.
- [17] Lei W, Churong L, Li P. Nasopharyngeal carcinoma: A Review of current updates. NCBI Journal. 2018. doi: 10.3892/etm.2018.5878.

HOMEMAILNEWSFINANCESPORTSENTERTAINMENTLIFESearchSHOPPINGYAHOO PLUSMORE...

Find messages, documents, photos or peopleAdvanced

mail+Upgrade Now

BennyHome

Compose

Inbox2.3K

Unread

Starred

Drafts19

Sent

Archive

Spam

Trash

Less

ViewsShow

FoldersHide

New Folder

Medscape251

Tutorial Fixunsyah

Unwanted

Back

Archive

Move

Delete

Spam

Yahoo/Inbox

[JUNPC] Editor Decision

Farhat Farhat<talenta@usu.ac.id>

To: Benny Kurnia, Fadhlia, Lily Setiani, Juniar, Ridha Chaharsyah Mulya

Tue, Mar 16, 2021 at 2:23 PM

Benny Kurnia, Fadhlia, Lily Setiani, Juniar, Ridha Chaharsyah Mulya:

We have reached a decision regarding your submission to INTERNATIONAL JOURNAL OF NASOPHARYNGEAL CARCINOMA, "27 Years Old Female with Early Stage Nasopharyngeal Carcinoma In Dr. Zainoel Abidin General Hospital Banda Aceh: A Rare Case".

Our decision is to: Accept Submission

Best regards

Editor In-Chief

Farhat Farhat

International Journal of Nasopharyngeal Carcinoma
Center of Excellence Nasopharyngeal Carcinoma,
4th Floor Hospital of the University Sumatera Utara

Settings

Farhat Farhat

talenta@usu.ac.id

Ikuti Kompetisi Demo

Dapatkan THR dengan mengikut kompetisi demo trading Valbury

All your memories in one place

without any limit

CASE REPORT

Young Woman with Early Stage Nasopharyngeal Carcinoma : A Rare Case

Abstract

Introduction: Nasopharyngeal carcinoma (NPC) is the most often cancer occurs in the head and neck. Early stage NPC is difficult to diagnose clinically, most NPC patients have been diagnosed in advanced stages. The study present a case of early-stage NPC with the symptoms of recurrent nosebleeds and headache which can be early symptom to suspect NPC.

Case Report: We reported a case of 27 year old woman patient with chief complaints recurrent nosebleeds since 2 months ago frequently one to two times a week. Patients also complained of mild headaches, but getting better by taking a rest and patient also had a history of tinnitus since 2 month ago. The patient has a habit of consuming salted fish and preservative food since childhood. Based on his history of illness, physical examination, imaging, and histopathology, we concluded that he was diagnosed with Nasopharyngeal Carcinoma T1N0M0, and the patient are going to reffered to North Sumatera or central java to get radiotherapy.

Conclusion: Early stage of nasopharyngeal cancer is a rare condition at Aceh, the fastest we found early stages will increased survival rate.

Keywords: Early symptom of nasopharyngeal carcinoma, nosebleeds , Headache.

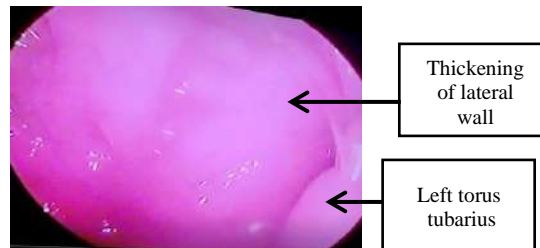
CASE REPORT

A 27 year old woman came to the Ear Nose Throat Head and Neck polyclinic-Dr. Zainal Abidin General Hospital Banda Aceh in January 2021. The patient complained of recurrent nosebleeds that had been experienced since the previous 2 months, nosebleeds is recurrent with a frequency of one to two times per week. The blood that comes out is not much, sometimes there are only blood spots when the patient blows his nose. In addition, patient also complained of mild headaches and getting better by taking a rest, but headaches often recur. Headache is felt especially on the forehead. Apart from that the patient also had a history of tinnitus. History of double eye vision and of lumps around the neck was denied.

The patient has a habit of consuming salted fish quite often, besides that the patient also likes to consume preservative foods such as instant noodles since childhood. There is no family member who has a history of cancer.

Anterior rhinoscopy examination found a minimal clot in the left nasal cavity, and no other abnormalities were seen.

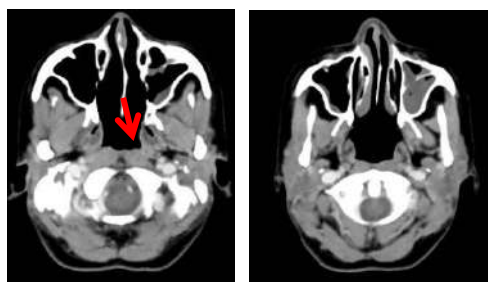
On 04th February 2021 the patient underwent a rigid nasopharyngoscopy examination at polyclinic to evaluate the cause of recurring nosebleeds. Before that, the patient underwent a screening of COVID-19 and the result of RT- PCR SARS-cov-2 was negative.



Picture 1. Rigid nasopharyngoscopy on February 04th 2021

The result of Rigid nasopharyngoscopy found there was a thickening at lateral left nasopharyngeal surface, especially around the fossa of rosenmüller. We did informed consent to performed a nasopharyngeal biopsy to determine the histopathology of thickening area. The biopsy was performed in Ear Nose Throat Head and Neck polyclinic under local anesthesia using biopsy forceps and 0 degrees rigid telescope and obtained 1 mm of tissue from the lateral left nasopharyngeal wall. Then the sample was sent to Pathology Anatomy Laboratory at Dr. Zainoel Abidin Hospital, after a week we got the histopathological result was non keratinizing squamous cell carcinoma.

On the 15th February 2021, we performed an HRCT of the nasopharynx with contrast and we have a result two day after.



Picture 2. CT scan of the nasopharynx using contrast showed thickening of the nasopharyngeal wall

The nasopharyngeal wall was thickened on a CT scan and there is no other visible mass and hypervascularisation. Based on history, physical examinations and all diagnostic procedure such as CT scan nasopharynx with contrast, Rigid nasopharyngoscopy plus biopsy, chest X-

rays and histopathologic result, we diagnosed a patient with nasopharyngeal carcinoma T1N0M0. We informed her to refer to North Sumatra or Central Java to have radiotherapy. We still do not have a central radiotherapy yet at our hospital.

DISCUSSION

At the pharyngeal recess or Fossa of Rosenmüller, the highest incidence of NPC inside the nasopharynx is found (82 percent), 12 percent occur in the midline and 6-10 percent of patients displayed normal endoscopic presence of nasopharyngeal mucosa. Fossa of Rosenmüller, which is superior and posterior to the Eustachian tube elevation. This fossa of Rosenmüller, which is coated with mixed stratified epithelium and ciliated epithelium with regions of a discontinuous attenuated reticular epithelium, is the lateral extension of the nasopharynx. So-called reticular epithelium in the nasopharyngeal regions, NPC can emerge from a special transitional epithelium and, It is likely that the origin of the cells could be [1]. In this case the tumour did not appear exophytic but highly suspicious as an asymmetric surface of both lateral surface of nasopharyngeal wall.

Generally in Indonesia especially Aceh it is very rare we found early stages of NPC. Dr. Zainoel Abidin General Hospital Banda Aceh as a top referral hospital in Aceh always received advanced diseases of NPC from all districts at Aceh. As we reported before in 2016-2017, The characteristic of NPC at Dr. Zainoel Abidin General Hospital Banda Aceh the most frequent was age ranged 41-60 years (44%), and incidence is higher in males than females and all of the subjects were locally advanced and advanced diseases. No one of them came in early stages [2]. Other study reported about nasopharyngeal carcinoma in childhood, the age ranged 12-16 years were 47%, and with the average age was 17.2 years [3]. The latest study reported in 2019, The youngest patient is 13 year old and the oldest is 79 year old. Most common average age are between 36-65 year old and none of all as an early stages [4]. Zhu yi in China reported Up to 87.6% of enrolled young patients with NPC were in an advanced stage (stage III or IV), and less than 15 % of patients can be diagnosed at an early stage and Tobing in Medan reported only 10% of NPC patients are likely to be diagnosed early at stage I. [5,6].

Sign and Symptoms of nasopharyngeal carcinomas frequently present with one or more of 4 groups of symptoms. They consist of otologic symptoms such as deafness and tinnitus, a small tumor in the fossa of Rosenmüller of the nasopharynx may cause Eustachian tube Nasal signs such as nasal obstruction, epistaxis, and discharge (these symptoms are related to the presence of tumor mass in the nasopharynx). Cranial nerve paralysis, normally 5th and 6th

cranial nerves, which is connected to the superior tumor extension contributing to skull base erosion, the patient may experience headache, diplopia, facial pain, and masses of numbness and neck.. Nasal signs such as nasal obstruction, epistaxis, and discharge (these symptoms are related to the presence of tumor mass in the nasopharynx). Cranial nerve paralysis, normally 5th and 6th cranial nerves, which is connected to the superior tumor extension contributing to skull base erosion, the patient may experience headache, diplopia, facial pain, and masses of numbness and neck. Severe headache is a symptom that arises due to the spread of the tumor to the anterior nerve groups are: N.III, NV, and NVI called the petrosphenoid syndrome. whereas parotidean syndrome occurs due to the spread of the tumor posterolaterally towards the parafarynx and the pterygopalatine fossa which enters the jugular foramen. nerves affected in this syndrome are the posterior brain nerve group, namely: NVII to NXII. In this patient there were no symptoms of parotidean syndrome. Headache from patient is not a sign of parotidean syndrome. [6,7]

Nasal obstruction, epistaxis, and discharge are all signs of nasal obstruction (these symptoms are related to the presence of tumor mass in the nasopharynx). The patient may experience headache, diplopia, facial pain, and masses of numbness and neck with cranial nerve paralysis, usually 5th and 6th cranial nerves, which is related to the superior tumor extension leading to skull base erosion. endoscope, however, is inferior to that of the rigid endoscope. This case presented recurrent nosebleed and mild headache. [8,9].

Computed tomography (CT) has long been utilized for staging nasopharyngeal carcinoma especially to detect skull base tumor involvement with lytic or sclerotic lesions. However, now, in some centers, MRI has replaced the use of CT for primary and nodal staging. MRI is considered to be an accurate examination to diagnose nasopharyngeal carcinoma. Subclinical nasopharyngeal carcinomas that are missed at endoscopy can be detected by MRI. Nasopharyngeal carcinomas in MRI usually present with intermediate signal intensity on T2 weighted images and low signal intensity on T1 weighted images. When suspicion of early-stage nasopharyngeal carcinoma arises, MRI can be an option if endoscopic examination does not reveal the expected signs. CT is still needed in radiotherapy planning [10,11].

We have sufficient facilities to worked up of NPC patient, but not the modality of treatment. Histopathology result is still as a gold standart for diagnosis of NPC. In Addition It remains unclear the precise contribution of EBV infection to NPC growth. In NPC tumor cells, the presence of monoclonal EBV episomes suggests that virus infection precedes the clonal expansion of the population of malignant cells. However, the absence of epithelial EBV infection from individuals at high risk of developing nasopharyngeal carcinoma in normal

nasopharyngeal biopsies indicates that epithelial infection may not be the initiating event of virus-associated carcinogenesis. IEBV infection as defined by in situ hybridization to the EBER RNAs is present in high-grade (severe dysplastic and carcinoma in situ) preinvasive lesions in the nasopharynx but not in low-grade disease or histologically normal nasopharyngeal epithelium. Both high-grade and carcinoma in situ lesions bear monoclonal EBV genomes. In high-grade (severe dysplastic and carcinoma in situ) preinvasive lesions in the nasopharynx but not in low-grade disease or histologically normal nasopharyngeal epithelium, EBV infection as identified by in situ hybridization to the EBER RNAs is found. Monoclonal EBV genomes are borne by both high-grade and carcinoma in situ lesions. [12,13].

There are three pathological subtypes of nasopharyngeal carcinoma: keratinizing squamous, non-keratinizing, and basaloid squamous, according to the World Health Organization. According to the World Health Organization, there are three pathological subtypes of nasopharyngeal carcinoma: keratinizing squamous, non-keratinizing, and basaloid squamous. Non-keratinizing nasopharyngeal carcinoma can be divided into differentiated and undifferentiated tumours. The non-keratinizing subtype constitutes most cases in endemic areas (>95%) and is predominantly associated with Epstein-Barr virus (EBV) infection. EBV can be detected in the tumor cells of almost all nonkeratinizing carcinoma but rarely in keratinizing nasopharyngeal carcinoma [12-14]. In addition, Almost 100 percent of WHO type III is associated with Epstein Barr Virus (EBV) infection, in particular. High IgG and IgA antibody responses to viral capsid antigen (VCA), early antigen (EA), and Epstein Barr Nuclear antigen (EBNA) suggest this (EBNA). 2-10 years before the appearance of the tumor, increased IgA NPC character antibodies can be identified. This occurs as a result of reactivation of EBV infection [15-17]. In our hospital we were not routinely doing the test for EBV. This patient show Non-keratinizing nasopharyngeal carcinoma as the result from histopathological examination, but there is no more explanation about type of differentiation from the tissues.

We routinely performed HRCT of nasopharynx with contrast to determine the stage of NPC at least for Tumour level (T) and locoregional metastasis (N) as well as laboratory test and ultrasonography and chest x-ray to looking for distant metastasis (M). We used TNM system from AJCC 8th edition 2017. The 2021 National Comprehensive Cancer Network (NCCN) guideline is used for the most recent staging system and management of head and neck malignancies [18].

Treatment and prognosis of nasopharyngeal cancer depend on the type of tissue, histological characteristics, and TNM staging. Patients with T1N0M0 nasopharyngeal carcinoma should be treated with definitive radiotherapy alone, including elective Radio therapy to the neck.

Radiotherapy alone is the standard treatment for early stage nasopharyngeal carcinoma and five-year overall survival rate of 84 to 90% can be achieved even with the use of conventional treatment technique. In general, patients with stage I and II nasopharyngeal carcinoma are treated by radiation only, whereas stage III and stage IV patients are treated by concurrent chemotherapy and radiation. In addition, evidence suggests that patients diagnosed with stage IV nasopharyngeal carcinoma with locally advanced disease may be better controlled by neoadjuvant cisplatin followed by chemoradiation. In this case, the patient was planned refer to hospital that can performed radiation therapy. For T1N0 patients, radiotherapy alone is given with a radical dose of 66-70 Gy daily Monday-Friday in 6-7 weeks [14].

Early-stage T1 and T2 nasopharyngeal cancers have very high (> 95%) 5-year locoregional control rates. The 5year overall survival rates are significantly lower, 70– 75%, emphasizing the propensity of these lesions to metastasize [18].

Since we do not have central radiotherapy, all the patient who had diagnosed as NPC with advanced stages, they underwent induction chemotherapy at Dr. Zainoel Abidin General Hospital Banda Aceh and if possible for them to continued radiotherapy in out of city.

A thorough examination and awareness of nasopharyngeal carcinomas early signs and symptoms will made it possible for clinicians to detect an early-stage nasopharyngeal carcinoma. Stage, WHO type and age at diagnosis are important prognostic factors for survival for nasopharyngeal carcinoma patients. With early diagnosing, we can deliver immediate therapy and will increase survival rate. Usually patient come to ENT specialist on advanced stage where complaints from patient are increasing and management to treat patient more complex [18].

However the early diagnosing of nasopharyngeal carcinoma can be difficult to determine because the post nasal space is relatively inaccessible examination, because of that the anamnesis must be clear. Early cancers of the nasopharynx produce minimal and trivial symptoms that may be neglected by the patients and undetected by physicians. Moreover, sometimes patients consult doctors of different specialties who have lack experience in managing nasopharyngeal carcinoma [15, 16]. Usually patient come to ENT specialist at advanced stage when neck node had appeared.

CONCLUSION

This case bring us new hope that awareness of early symptom of NPC have arised at community based. The patient came from west Aceh where geographically about 300

kilometres far away from Banda Aceh. The Insurance from government also give contribution to get more easier to medical access.

REFERENCE

- [1] Anne WML, Maria LL, Wai TN. Nasopharyngeal Carcinoma; From etiology to clinical practise. United Kingdom: Elsavier publisher; 2019. Page 46-47.
- [2] Kurnia B, Kamarlis RK, Kamal FK. Characteristic of Nasopharyngeal Carcinoma in Aceh 2016-2017. International journal of nasopharyngeal carcinoma. 2019, Vol. 01, No. 01, 2019 | 24-29. DOI: 10.32734/ijnpc.v1i1.958
- [3] Setiani L, Fadhlia, Kurnia B, Karnita Y. Characteristics of Nasopharyngeal Carcinoma in Children and Adolescents in dr. zainoel abidin general hospital banda aceh. International journal of nasopharyngeal carcinoma. 2019, Vol. 01, No. 03, 2019; 93-96. DOI: 10.32734/ijnpc.v1i03.2062.
- [4] Fadhlia, Ferawati, Irnawati. Management of Nasopharyngeal Cancer in DR. Zainoel Abidin General Hospital Banda Aceh. International journal of nasopharyngeal carcinoma. 2019, Volume 1, No 1, 2019 | 50-54. DOI: 10.32734/ijnpc.v1i2.1 | 34
- [5] Zhu y, Song X, Li R, Quan H, Yan L. Assesment of Nasopharyngeal Cancer in Young Patients Aged < 30 Years. Frontiers in Oncology. 2019, Vol 9. DOI : 10.3389/fonc.2019.01179.
- [6] Tobing IN. Early-stage Nasopharyngeal Carcinoma: A Case Report. International journal of nasopharyngeal carcinoma. 2019, Vol. 01, No. 02, 2019 | 75-77. DOI: 10.32734/ijnpc.v1i2.1133.
- [7] Yvonne C, John CG. K.J.LEE'S Essential Otolaryngology Head and Neck Surgery. Eleventh Edition. New York: McGraw-Hill Education; 2016. Page 722.
- [8] Ashley W, James BS. Ballenger's Otolaryngology Head and Neck Surgery 18. United Kingdom: People's Medical Publishing House; 2016. Page 4389, 4397.
- [9] Network NCC. NCCN Clinical Practice Guidelines in Oncology (NCCN® guidelines): head and neck cancers. Version 1.2021.
- [10] Tobing IN. Early-stage Nasopharyngeal Carcinoma: A Case Report. International journal of nasopharyngeal carcinoma. 2019, Vol. 01, No. 02, 2019 | 75-77. DOI: 10.32734/ijnpc.v1i2.1133.

- [11] Tsang CM, Lo KW, Nicholls JM, Huang SCM, Tsao SW. Pathogenesis of Nasopharyngeal Carcinoma: Histogenesis, EpsteinBarr Virus Infection, and Tumor Microenvironment. Elsevier Inc: China; 2018. Page 60.
- [12] Chen YP, Chan AT, Blanchard P, Sun Y, Jun-ma. Nasopharyngeal Carcinoma. The lancet Journal. 2019, Volume 394. [http://dx.doi.org/10.1016/S0140-6736\(19\)30956-0](http://dx.doi.org/10.1016/S0140-6736(19)30956-0).
- [13] Shah J, Patel S, Singh B, Wong R. Jatin Shah's Head and Neck Surgery and Oncology. Fifth Edition. Elsevier: Sidney; 2020. Page 299.
- [14] Flint PW, Haughey BH, Lund VJ, Niparko JK, Robbins KJ, Thomas JR, Lesperance MM. Cummings Otolaryngology Head and Neck Surgery. Sixth Edition Volume 1. Saunders Elsevier: Philadelphia; 2015. Page 1423.
- [15] John CW, Raymond WC. Scott-Brown's Otolaryngology Head and Neck Surgery Volume three. Eighth Edition. France: CRC Press; 2019. Page 93.
- [16] Adham M, Zhafira AS, Paramitha AC, Adhyatmoko B, Hanafi G, Hiksas R, Culham K. The Importance of Early Detection of Nasopharyngeal Carcinoma: A Case Report in Scientific Paper Compilation 1st National Conference of Nasopharyngeal Carcinoma, Prevention is better than cure. USU Press: Medan; 2018. Page 136.
- [17] Lalwani AK. Current Diagnosis and Treatment Otolaryngology Head and Neck Surgery. Second edition. Mc Graw Hill Lange: United State of America; 2008. Page 1423.
- [18] Lei W, Churong L, Li P. Nasopharyngeal carcinoma: A Review of current updates. NCBI Journal. 2018. doi: 10.3892/etm.2018.5878.